



CHARACTERIZATION OF MORPHOLOGICAL BRAIN CHANGES IN GENERALIZED EPILEPSY USING REGION BASED MORPHOMETRY

Wimalasiri DMDT¹, Rajapaksha SRAL¹, Zhang X², Sampath WKC³ and Ediri Arachchi WM¹

Department of Radiography and Radiotherapy, Faculty of Allied Health Sciences, General Sir John Kotelawala Defence University, Sri Lanka¹

School of Meical Imaging, Tianjin Medical University, China²
Department of Radiology, University Hospital KDU, Sri Lanka³

ABSTRACT

Magnetic Resonance Imaging has been widely involved in detecting morphological brain changes in generalized epilepsy at voxel level. It is believed that region-based morphometry could provide better characterizations for macro structural changes in the brain with comparative advantages than voxel-based morphometry. The aim of this study is to detect regional brain changes associated with generalized epilepsy and to test the potential of regional brain changes in classification of patients with generalized epilepsy and non-epileptic subjects. 45 patients and 46 non-epileptic subjects were scanned using a 3 Tesla MRI scanner and 3D T1 weighted images were obtained. Images were pre-processed and region based structural metrics (grey matter volumes, white matter volumes, cerebrospinal fluid volumes, cortical gyrification, and sulcus depth) were developed using Computational Anatomical Toolbox (CAT12). Two sample t-tests were used to perform the univariate analyses and results were corrected for multiple comparisons (FDR corrected, $p < 0.05$). Grey matter volume reductions were detected in cerebellum, frontal lobe, temporal lobe, thalamus, and hippocampal region while bilateral white matter volume reductions were reported in cerebellum. In contrast, cerebrospinal fluid volume increments in left lateral ventricle were also detected. Reduced regional gyrification was detected in left posterior ramus of the lateral sulcus and reduced sulcal depths were detected in occipital pole, cuneus, and posterior ramus of the lateral sulcus in patients. Furthermore, pattern analysis revealed that each metric shows different discriminative abilities to distinguish patients with generalized epilepsy and non-epileptic subjects (Classification accuracy: 61.1%, 62.2%, 58.8%, 61.1% and 60% for GMV, WMV, CSFV, Cortical gyrification and sulcal depth respectively). In conclusion, this study provides a comprehensive understanding about regional structural changes (cortical and subcortical) associated with generalized epilepsy under region-based morphometry. However, pattern analyses do not provide adequate discriminative power and therefore the clinical utility of findings is limited.

KEYWORDS: *Generalized epilepsy, Grey matter, White matter, Cerebrospinal fluid, Cortical gyrification, Sulcus depth, Region based morphometry, Classification*

Corresponding Author: WM Ediri Arachchi, Email: wasmadushanka@kdu.ac.lk



<https://orcid.org/0000-0003-3750-8070>



This is an open-access article licensed under a Creative Commons Attribution 4.0 International License (CC BY) allowing distribution and reproduction in any medium crediting the original author and source.

1. INTRODUCTION

Epilepsy is one of the most prevalent neurological conditions of the human brain that affects 70 million people in the world. It has several psychological, cognitive, and neurological consequences, and most people with epilepsy are untreated (Thijs *et al.*, 2019).

The process which converts a healthy brain into one possible recurrent seizure is called epileptogenesis. This happens due to imbalance of inhibitory activity and excitatory activity within a neuronal network. As a result of this imbalance, there will be an excessive synchronization of function. It will cause disruption of normal neuronal networks and is able to interrupt other neuronal networks too (Thijs *et al.*, 2019, Fisher *et al.*, 2014).

According to the updated epilepsy classification, it is categorized into four types according to the onset of the disease, which are focal epilepsy, generalized epilepsy, combined generalized, and focal epilepsy and unknown onset (Fisher *et al.*, 2014, Fisher *et al.*, 2017). If abnormal electrical activity occurs in one hemisphere, it is called focal epilepsy and if an abnormal electrical activity occurs in both hemispheres, it is called generalized epilepsy (Thijs *et al.*, 2019).

For over a decade, MRI has been used for epilepsy research and with the development of MRI, the examination and management of patients with epilepsy have undergone a revolutionary change (Oldendorf, 1984, Sostman *et al.*, 1984). According to the current evidence, neuroimaging scientists prove that there is a specific standard protocol for structural imaging, and it is balanced with clinical optimization and diagnostic accuracy. The protocol involves identifying malformations of cortical development, spot abnormalities of the hippocampus, to hippocampal sclerosis and focal cortical dysplasia, vascular and calcified lesions (Sidhu *et al.*, 2018).

Region Based Morphometry (RBM) is a method that is used to detect structural abnormalities region by region using probabilistic atlas maps. The regional volumes inside the region of interest (ROI) are detected for each tissue type (grey matter, white matter, and CSF) at native space of each brain and the

estimated central surface is used to quantify ROI based surface values such as cortical gyrification and sulcus depth at native space (Tu *et al.*, 2022).

Many Investigators have used voxel-based morphometry as an image processing method because it is applied in the whole brain, but it can be done as a comparison within different anatomical areas of the brain separately and more accurately by using Region based morphometry (Giuliani *et al.*, 2005). So, it has been discussed that the region-based morphometry could provide better characterizations for macro structural changes in the brain with comparative advantage than voxel-based morphometry (Li *et al.*, 2010).

As evidenced by previous studies, certain morphological brain changes associated with generalized epilepsy were detected by RBM. All types of epilepsies had lower normal brain volume and lower gray matter volumes in amygdala, frontal lobe, thalamus, putamen and caudate compared to healthy controls (Betting *et al.*, 2006, Ke *et al.*, 2017, Li *et al.*, 2010). Furthermore, the latest evidence about that cerebellum acting as major area which showed reduced volume of both gray matter and white matter of patients who are with Idiopathic generalized epilepsy (Li *et al.*, 2010).

The white matter integrity in idiopathic generalized epilepsy using tractography and ROI analysis has revealed significantly lower fractional anisotropy (FA) values of six white matter tracts related to the cerebellum (Liu *et al.*, 2011). The morphological abnormalities related to CSF in lateral ventricles in patients with generalized epilepsy over healthy subjects proved that left lateral ventricle was enlarged (Betting *et al.*, 2006).

A previous study has been conducted to observe several cortical changes such as cortical folding (gyrification), cortical developments and surface area. The researchers detected the following results for each hemisphere. Cortical developments were detected in several cortical regions, insula, cingulate cortex, temporal pole of temporal lobe and occipital pole of occipital lobe in the left hemisphere and cortical morphology changes were detected in insula, temporal

pole and precuneus in the right hemisphere.(Oyegbile *et al.*, 2004).

Comparing the findings of different structural metrics of different studies is difficult as they involved different sample sizes, different data processing strategies and different diagnostic stages of subjects. Therefore, a direct comparison of multiple structural metrics is necessary to understand how generalized epilepsy affects the human brain. We utilized multiple structural metrics to characterize regional brain changes in generalized epilepsy using region-based morphometry. Further, we tested the potential of using different region-based metrics in classification of patients with generalized epilepsy and non-epileptic subjects using multivariate pattern analysis (MVPA).

2. METHODOLOGY

Subjects

45 patients with generalized epilepsy and 46 non-epileptic subjects were included in the study. This cross-sectional study was approved by the ethics review committees of Faculty of Medicine, General Sir John Kotelawala Defence University, Sri Lanka. All the patients and the non-epileptic subjects were checked by an experienced consultant Neurologist and consultant Radiologist of University Hospital, KDU (UH-KDU). The patients were diagnosed by a neurologist using diagnostic manual published by International League Against Epilepsy (ILAE) by the evaluations including patient history, electroencephalography (EEG) recordings and neuropathological examination. All the patients with the absence of systemic medical illnesses or other central nervous system disorders, and with no history of traumatic head injuries or substance abuse were included in the study. First-degree relatives with epilepsy or other epilepsy syndromes were considered for an additional exclusion criterion of non-epileptic subjects.

Magnetic Resonance Image Acquisition

MRI data was acquired using a 3.0 Telsa MRI scanner (Philips) and an 8-channel head coil. 3D T1-Weighted images were collected using turbo spin echo (TSE) sequence. The specific parameters used in this process include an 8 ms repetition time (TR), and 4 ms echo

time (TE), 8 degrees flip angle (FA), a 256 mm × 256 mm field of view (FOV), a 256 × 256 matrix, 1 mm slice thickness and no gap, and 170 slices in sagittal planes. The head was securely positioned using ear plugs and foam pads during the scanning process.

Image Preprocessing

Raw Images (DICOM) were converted to NiFTI format and verified to align with the same orientation as the reference images available in the Statistical Parametric Mapping 12 (SPM12) software. Preprocessing was conducted utilizing the Computational Anatomy Toolbox 12 (CAT12) and pipeline included bias field correction, local and global intensity normalization, and noise reduction. Additionally, all brain images underwent skull stripping using adaptive probability region-growing (APRG) techniques. Then, the preprocessed images underwent RBM analysis using CAT12 toolbox.

Region Based Morphometry

Brain segmentation into GM, WM and CSF tissue categories was done using integrated Markov Random Field and Adaptive Maximum a posterior segmentation procedure. These methods are designed to minimize reliance on tissue probability maps, enhancing accuracy in the segmentation process. CAT 12 enables estimation of tissue volumes for different regions and surfaces using atlas maps called neuromorphometrics and aparc2009 respectively. The tissue volumes inside the region of interest (ROI) were detected for each tissue type (grey matter, white matter, and CSF) at native space of each brain. Cortical surfaces were reconstructed using projection-based thickness (PBT) method. The estimated central surface was used to quantify ROI based surface values for cortical gyrification and sulcus depth at native space (Tu *et al.*, 2022).

Univariate Statistical Comparisons

CAT 12 enables statistical comparisons in region-based estimations through the 'ROI analysis' module. Group level Differences between individuals with epilepsy and non-epileptic subjects in regional grey matter, white matter, cerebrospinal fluid volumes, cortical gyrification, and sulcus were identified using

two-sample t-tests. The inter-individual differences of brain sizes were accounted using Total intracranial volumes (TIV) of each subject. The findings were eventually adjusted for false discovery rate (FDR) to account for multiple comparisons ($p < 0.05$).

Multivariate Pattern Analysis

Multivariate pattern analyses (MVPA) were conducted to compare generalized epilepsy patients with non-epileptic subjects using whole brain regional volumes (ROI-based values of GM, WM, and CSF) and surface values (ROI-based values of cortical gyrification and sulcal depth). The analysis was performed utilizing the MVPANI toolbox (<http://funi.tmu.edu.cn>) in conjunction with the linear support vector machine implementation in LibSVM. All participants were divided into 91 folds, with the initial 45 subjects consisting of individuals with epilepsy and the subsequent 46 subjects comprising non-epileptic individuals.

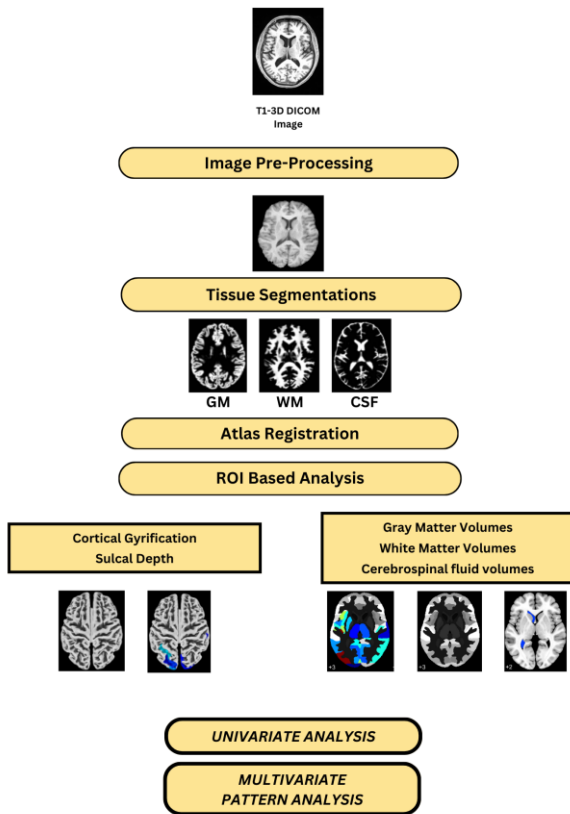


Figure 1: Image-processing Workflow of Region-based Morphometry (GM, grey matter; WM, white matter; CSF, cerebrospinal fluid)

To assess the classification performance, a linear support vector machine (SVM) and the leave-one-subject-out cross-validation method were utilized across all 91 subjects. The mean accuracy of classification was determined through this procedure. During each cross-validation iteration, a classifier was trained using training dataset (90 folds) and tested on the remaining dataset (1-fold), resembling the training dataset that resulted in classification accuracy for the cross-validation step. The significance of the final accuracy was evaluated against chance level accuracy using permutation tests ($n=5000$), with the corresponding p-value calculated. Specifically, the p-value indicated the proportion of permutations where the classification accuracy equalled or surpassed the observed accuracy. A p-value of $p < 0.0002$ ($1/5000$) was assigned if the observed accuracy was approached by none of the 5000 permutations (Ediri Arachchi et al., 2020). Image processing steps are shown in Figure 1.

3. RESULTS

Univariate Statistical Comparisons

We found widespread regional volume reduction in gray matter, a slight volume reduction in white matter and a slight volume increase in CSF in generalized epilepsy compared to non-epileptic subjects as shown in Figure 2 and results are summarized in Table 1. The regional cortical changes (reduced cortical gyrification and sulcus depth) are shown in Figure 3 with the results summarised in Table 2 respectively.

Gray matter volume reductions were detected in inferior occipital gyrus, cerebellum exterior, transverse temporal gyrus, cuneus, occipital fusiform gyrus, middle temporal gyrus, thalamus Proper, calc calcarine cortex, lingual gyrus, and superior occipital gyrus bilaterally. Besides, frontal operculum, posterior insula, anterior orbital gyrus, planum temporale, angular gyrus, middle occipital gyrus, planum polare, anterior insula, posterior cingulate gyrus, parietal operculum, central operculum, lingual gyrus, precuneus, gyrus rectus, basal forebrain and occipital

pole regions were detected unilaterally in the left hemisphere. Further, temporal pole, hippocampus, posterior orbital gyrus, superior temporal gyrus, superior temporal gyrus, fusiform gyrus and inferior

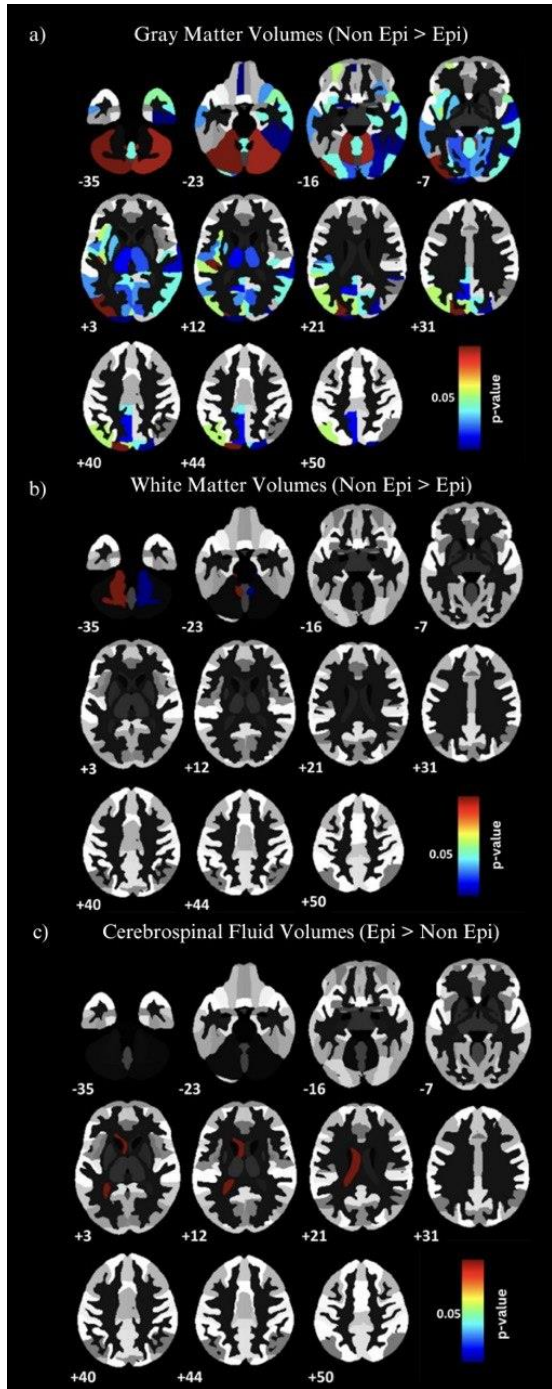


Figure 2: Regional grey matter volume reductions in patients with generalized epilepsy compared to non-epileptic subjects detected by Region-based morphometry (panel a), regional white matter volume

reductions (panel b) and cerebrospinal fluid volume increment (panel c). All detected areas, indicated in blue to red (corresponding p values obtained from two-sample t tests), had reduced GM, WM volumes and increased CSF volume in patients with generalized epilepsy compared with non-epileptic subjects. ($p < 0.05$, FDR Corrected).

temporal gyrus were detected unilaterally in the right hemisphere of patients with generalized epilepsy (Figure 2a).

A notable volume reduction in white matter was found to be significant in cerebellum (Figure 2b) and an increment of CSF volume was reported in the left lateral ventricle (Figure 2c).

Table 1: Regional gray matter, white matter volume reductions and cerebrospinal fluid volume increment detected by region-based morphometry (RBM) in patients with generalized epilepsy compared to non-epileptic subjects.

Hemisphere	Region (Neuromorphometrics atlas)	T value	P value
GM volume changes			
Left hemisphere	Inferior occipital gyrus	4.3	0.001
	Cerebellum Exterior	4.1	0.001
Right hemisphere	Transverse temporal gyrus	4.1	0.001
	Frontal operculum	4.1	0.001
	Posterior insula	3.7	0.003
	Cun cuneus	3.6	0.003
	Anterior orbital gyrus	3.6	0.003
	Planum temporale	3.6	0.003
	Angular gyrus	3.5	0.003
	Middle occipital gyrus	3.5	0.003

	Occipital fusiform gyrus	3.5	0.003
	Planum polare	3.3	0.004
	Anterior insula	3.2	0.004
	Posterior cingulate gyrus	3.2	0.004
	Parietal operculum	3.2	0.004
	Putamen	3.2	0.005
	Middle temporal gyrus	3.1	0.005
	Calc calcarine cortex	3.1	0.005
	Central operculum	3.0	0.006
	Lingual gyrus	3.0	0.007
	Thalamus Proper	3.0	0.007
	Precuneus	2.9	0.009
	Gyrus rectus	2.7	0.009
	Basal forebrain	2.9	0.009
	Occipital pole	2.8	0.009
	Superior occipital gyrus	2.7	0.001
	Cerebellum exterior	4.0	0.001
Right hemisphere	Temporal pole	3.4	0.003
	Hippocampus	3.4	0.004
	Transverse temporal gyrus	3.3	0.004
	Inferior occipital gyrus	3.3	0.004
	Middle temporal gyrus	3.2	0.004
	Cun cuneus	3.2	0.004
	Lingual gyrus	3.1	0.005
	Posterior orbital gyrus	3.0	0.005

	Thalamus Proper	3.0	0.006
	Superior temporal gyrus	3.0	0.006
	Calc calcarine cortex	2.8	0.008
	Superior occipital gyrus	2.8	0.008
	Occipital fusiform gyrus	2.8	0.008
	Fusiform gyrus	2.7	0.009
	Inferior temporal gyrus	2.7	0.009
WM volume changes			
Left hemisphere	Cerebellum White Matter	3.9	0.0008
Right hemisphere	Cerebellum White Matter	3.6	0.0010
CSF volume changes			
Left hemisphere	Left Lateral ventricle	2.5	0.006

A slight reduction of cortical gyrfication was detected in the posterior ramus of the lateral sulcus of left hemisphere as shown in Figure 3a. A considerable reduction of sulcus depth was detected in planum polare of the superior temporal gyrus, posterior ramus of the lateral sulcus, occipital pole, inferior segment of the circular sulcus of the insula, and anterior transverse temporal gyrus bilaterally. In addition, anterior transverse collateral sulcus, intraparietal sulcus and transverse parietal sulci, para hippocampal gyrus, para hippocampal region of the medial occipital-temporal gyrus, superior segment of the circular sulcus of the insula, superior occipital gyrus, medial occipito-temporal sulcus (collateral sulcus) and lingual sulcus, superior occipital sulcus and transverse occipital sulcus regions were detected for sulcus depth reductions in left hemisphere. Furthermore, transverse

temporal sulcus, cuneus, planum temporale or temporal plane of the superior temporal gyrus were detected for sulcus depth reduction in right hemisphere as shown in Figure 3b.

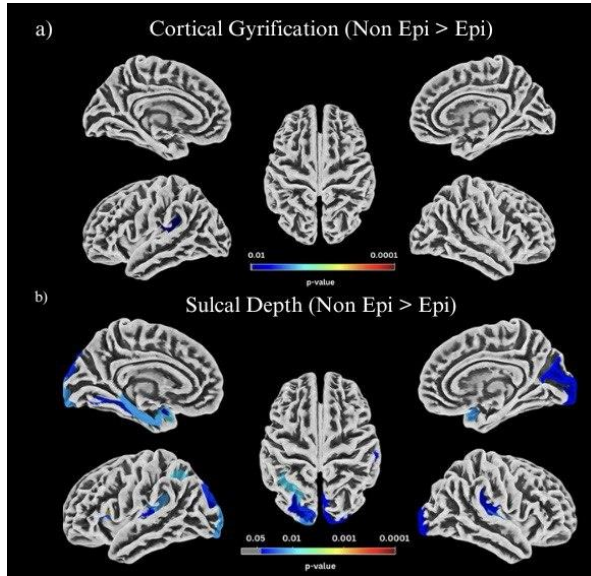


Figure 3: Regional cortical gyrification surface value reductions (panel a) and regional sulcal depth surface value reductions (panel b) in patients with generalized epilepsy compared to non-epileptic subjects detected by region-based morphometry. All detected areas, indicated in blue to red (corresponding to p values obtained from two-sample t tests), had reduced cortical gyrification and sulcus depth surface values in patients with generalized epilepsy compared with non-epileptic subjects. ($p < 0.05$, FDR Corrected). The regions are displayed based on aparac2009 atlas.

Table 2: Regional cortical gyrification and sulcal depth reductions detected by region-based morphometry (RBM) in patients with generalized epilepsy compared to non-epileptic subjects.

Hemisphere	Atlas region (Aparc 2009)	T value	P value
Cortical gyrification			
Left	Posterior ramus of	4.0	0.009

Hemisphere	the lateral sulcus		
Sulcal Depth			
Left Hemisphere	Vertical ramus of the anterior segment of the lateral sulcus	4.6	0.001
	Anterior transverse collateral sulcus	4.0	0.004
	Intraparietal sulcus and transverse parietal sulci	4.0	0.009
	Planum polare of the superior temporal gyrus	3.6	0.009
	Posterior ramus of the lateral sulcus	3.2	0.013
	Occipital pole	3.2	0.013
	Para hippocampal gyrus, Para hippocampal part of the medial occipital-temporal gyrus	3.2	0.013
	Superior segment of the circular sulcus of the insula	2.9	0.024
	Superior occipital gyrus	2.8	0.028
	Medial occipito-temporal sulcus (collateral sulcus) and lingual sulcus	2.8	0.032
	Inferior segment of the circular sulcus of the insula	2.6	0.038
	Superior occipital sulcus and transverse occipital sulcus	2.6	0.038

	Anterior transverse temporal gyrus	2.6	0.040
Right Hemisphere	Planum polare of the superior temporal gyrus	3.3	0.013
	Anterior transverse temporal gyrus	3.2	0.013
	Transverse temporal sulcus	3.1	0.019
	Inferior segment of the circular sulcus of the insula	3.0	0.023
	Posterior ramus of the lateral sulcus	2.6	0.038
	Occipital pole	2.6	0.038
	Cuneus	2.6	0.038
	Planum temporale or temporal plane of the superior temporal gyrus	2.5	0.040

Pattern classification analyses were performed to classify patients with generalized epilepsy and non-epileptic subjects. These analyses were based on different structural measures such as grey matter volumes, white matter volumes, cerebrospinal fluid volumes, cortical gyrification and sulcus depth. The pattern analysis revealed that each metric shows discriminative power to distinguish patients and non-epileptic subjects (Classification accuracy: 61.1%, 62.2%, 58.8%, 61.1% and 60% for GMV, WMV, CSFV, cortical gyrification and sulcal depth respectively). Pattern classification accuracies and corresponding null distributions are shown in Figure 4.

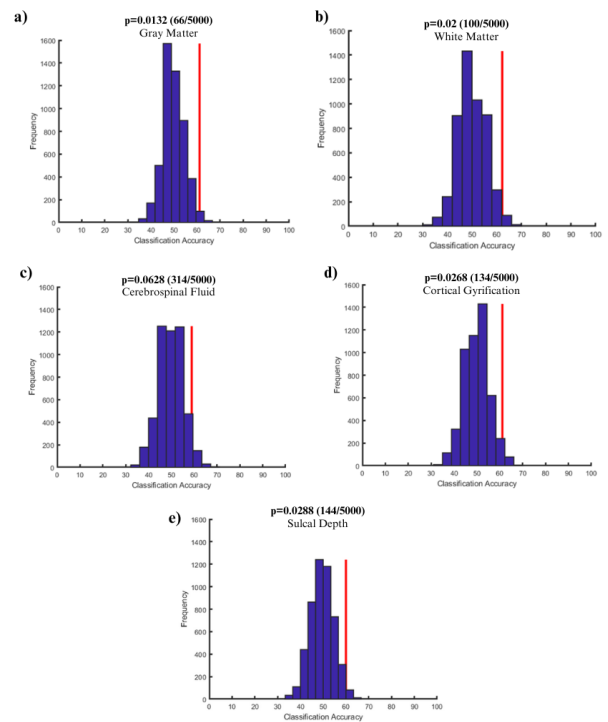


Figure 4: Pattern classification accuracies of WM, GM, CSF, Cortical gyrification, and Sulcal depth of patients with generalized epilepsy differentiated with non-epileptic subjects using 5000 permutation tests.

The classification accuracy is represented by red straight lines, while null distributions from 5000 permutations are represented by bell-shaped GM, WM, CSF, Cortical gyrification and Sulcal depth distributions with 50% center point. The percentage of number of permutations that were greater than or equal to the actual classification accuracy was used to derive the p values. (p-value for GM – 0.0132, p-value for WM – 0.02, p-value for CSF – 0.0628, p value for cortical gyrification – 0.0268 and p-value for sulcal depth- 0.0288)

4. DISCUSSION

We used Region Based Morphometry to characterize morphological brain changes in generalized epilepsy over non-epileptic subjects. We found significant morphological changes for multiple metrics considered in our study. Further, the above metrics have been well performed in classifying patients and non-epileptic subjects.

A limited number of studies have been performed for generalized epilepsy using RBM and most of them have been confined to one type of metric. Our study being comprehensive and systematic work, we used both volume (GM, WM, and CSF) and surface parameters (cortical gyrification and sulcus depth) in the same study. We believe that these findings could provide a better insight into structural characteristics of brain cortex and sub-cortex in patients with generalised epilepsy.

As strengths of using region-based morphometry, it makes possible due to pre specified areas that were used to find cortical volume differences. Besides, the ROI method shows anatomical validity subsequently and absolute volume values of the voxels of specified regions compared to the given results of concentration of voxels by VBM. In VBM the brains are analysed at voxel level and therefore it is more prone to multiple comparison errors at statistical analysis. In contrast to VBM, RBM shows less multiple comparison errors as the comparison is performed between limited number of regions (Giuliani *et al.*, 2005, Seyedi *et al.*, 2020).

Grey matter volume reductions detected in our study (cerebellum, frontal lobe, temporal gyri, thalamus, and hippocampal region) have been well repeated by many previous studies in different extent (Betting *et al.*, 2006, Ciumas and Savic, 2006, Daswatta *et al.*, 2023, Ke *et al.*, 2017). The study (Ciumas and Savic, 2006) detected volume reductions as follows, cerebellum (Epi : $56.6 \pm 6.9 \text{ cm}^3$, Hc : $67.8 \pm 6.9 \text{ cm}^3$), thalamus (Epi : $6.5 \pm 0.6 \text{ cm}^3$, Hc : $7.2 \pm 0.6 \text{ cm}^3$), hippocampus (2.3 ± 0.6 , Hc : 2.3 ± 0.4), caudate (Epi : $4.2 \pm 0.5 \text{ cm}^3$, Hc : $4.9 \pm 0.5 \text{ cm}^3$), putamen (Epi : $56.6 \pm 6.9 \text{ cm}^3$, Hc : $5.9 \pm 0.5 \text{ cm}^3$), amygdala (Epi : $1.6 \pm 0.3 \text{ cm}^3$, Hc : $1.6 \pm 0.4 \text{ cm}^3$). However, apart from most of the literature, several regional grey matter volume reductions in our study were only reported unilaterally (right hippocampus, right fusiform, right superior frontal, right inferior occipital, right superior parietal and left post central, left thalamus, left middle frontal, left putamen, left insula). Other than that, our study observes reduced GM volume in cingulate gyrus bilaterally, and another study selected 6 ROIs of cingulate cortex (t values: 3.35, 3.45, 4.13, 4.24, 3.20, 3.14 for left anterior, right anterior, left middle, right

middle, left posterior, right posterior respectively) for which reduced GM volumes (Ke *et al.*, 2017).

White matter volume reductions detected in our study bilaterally in cerebellum have been well repeated by many previous studies in different extent. The study (Li *et al.*, 2010) revealed that FA values were significantly lower in AAL regions of cerebellum -6-R and cerebellum -4-5-R unilaterally in the right hemisphere. (p values: 0.002). Another study revealed significant lower FA values of 6 white matter tracts related to the cerebellum (Liu *et al.*, 2011). Moreover, (Betting *et al.*, 2006) found that there were WM abnormalities in frontal lobe bilaterally.

Amongst the limited number of studies which were performed to detect CSF changes in generalised epilepsy patients over non-epileptic subjects, stated that there was an enlargement of left lateral ventricle while our study also detected and described a slight increment of CSF in left lateral ventricle (Betting *et al.*, 2006). Fraction of CSF was increased (pre-and postcentral gyrus, superior, middle, inferior, medial frontal gyrus) according to another study (Ciumas and Savic, 2006).

Only a limited number of research studies have been performed to observe gyrification and sulcal depth. Similar results in comparison to our study showed in the regions which were occipital pole of occipital lobe, insula in left hemisphere unilaterally, cuneus in right hemisphere unilaterally and temporal pole of temporal lobe bilaterally with Oyegbile *et al.*, 2004 study. Apart from that, this study observes a reduction of cortical gyrification in the left posterior ramus of the lateral sulcus unilaterally and anterior transverse collateral sulcus, intraparietal sulcus and transverse parietal sulci, para hippocampal gyrus, para hippocampal region of the medial occipital-temporal gyrus, lingual sulcus and regions were detected for sulcus depth reductions in the left hemisphere. Furthermore, transverse temporal sulcus, cuneus, planum temporale or temporal plane of the superior temporal gyrus were detected for sulcus depth reduction in right hemisphere.

Our study can be considered as the first evidence for differentiating patients with epilepsy and non-epileptic subjects by using multiple structural metrics under region-based morphometry. This study used both volumetric values and surface values for multivariate comparisons of regional morphological changes of epilepsy patients over non-epileptic subjects. More specifically, white matter had the highest classification accuracy of 62.2 % and 61.1 % for gray matter, 58.8 % for cerebrospinal fluid. According to the surface data, cortical gyrification had 61.1 % classification accuracy and 60% sulcal depth as well. Overall, poor CSF changes detected in epilepsy patients as compared to gray matter and white matter changes may be the cause of the reduced classification accuracy of CSF in differentiating between the epilepsy and non-epileptic subjects.

We observed several limitations in the study. Since this is a cross-sectional study, the study was conducted based on the data available on the radiology database. Therefore, it was difficult to find some baseline characteristics such as age, gender and clinical data on all subjects in the database. Then, the sample size was limited and that may have contributed to reduced statistical power and we were unable to conduct further subgroup analysis due to the modest sample size. The clinical impact of the above morphological changes was not considered in this study due to the cross-sectional nature of the design. Further, it would be better to determine dynamic brain developments by examining the changes over time in future studies.

5. CONCLUSION

In conclusion, our research study provides a comprehensive understanding about regional morphological changes associated with generalized epilepsy using region-based morphometry. It describes both cortical and sub-cortical regional volume changes associated with generalized epilepsy. Furthermore, the multivariate approach provides low accuracies that may not be instrumental for applying clinical diagnosis of the condition.

6. REFERENCES

Betting, L. E., Mory, S. B., Lopes-Cendes, I., Li, L. M., Guerreiro, M. M., Guerreiro, C. A. & Cendes, F.

(2006). MRI reveals structural abnormalities in patients with idiopathic generalized epilepsy. *Neurology*, 67, pp.848-52.

Ciomas, C. & Savic, I. (2006). Structural changes in patients with primary generalized tonic and clonic seizures. *Neurology*, 67, pp.683-6.

Daswatte, M. R. A. U., Grero, P. R., David, A. A., Jayarathne, R. E. P., Pallegatte, A. S. & Ediri Arachchi, W. M. (2023). A Systematic Characterization of Structural Brain Changes in Epilepsy Using Magnetic Resonance Imaging. *KDU J. of Multidisciplinary Studies*, 5, pp.1-9.

Ediri Arachchi, W., Peng, Y., Zhang, X., Qin, W., Zhuo, C., Yu, C. & Liang, M. 2020. A Systematic Characterization of Structural Brain Changes in Schizophrenia. *Neuroscience Bulletin*, 36, 1107-1122.

Fisher, R. S., Acevedo, C., Arzimanoglou, A., Bogacz, A., Cross, J. H., Elger, C. E., Engel, J., Jr., Forsgren, L., French, J. A., Glynn, M., Hesdorffer, D. C., Lee, B. I., Mathern, G. W., Moshe, S. L., Perucca, E., Scheffer, I. E., Tomson, T., Watanabe, M. & Wiebe, S. (2014). ILAE official report: a practical clinical definition of epilepsy. *Epilepsia*, 55, pp.475-82.

Fisher, R. S., Cross, J. H., D'souza, C., French, J. A., Haut, S. R., Higurashi, N., Hirsch, E., Jansen, F. E., Lagae, L., Moshe, S. L., Peltola, J., Roulet Perez, E., Scheffer, I. E., Schulze-Bonhage, A., Somerville, E., Sperling, M., Yacubian, E. M. & Zuberi, S. M. (2017). Instruction Manual For The Ilae 2017 Operational Classification Of Seizure Types. *Epilepsia*, 58, Pp.531-542.

Giuliani, N. R., Calhoun, V. D., Pearlson, G. D., Francis, A. & Buchanan, R. W. (2005). Voxel-Based Morphometry Versus Region Of Interest: A Comparison Of Two Methods For Analyzing Gray Matter Differences In Schizophrenia. *Schizophr Res*, 74, Pp.135-47.

Ke, M., Jin, B., Liu, G. & Yang, X. (2017). Impairments Of Cingulate Cortex In The Generalized Tonic-Clonic Seizure Epilepsy By Combining

- Morphological And Functional Connectivity Magnetic Resonance Imaging. *J Integr Neurosci*, 16, Pp.429-439.
- Li, Y., Du, H., Xie, B., Wu, N., Wang, J., Wu, G., Feng, H. & Jiang, T. (2010). Cerebellum Abnormalities In Idiopathic Generalized Epilepsy With Generalized Tonic-Clonic Seizures Revealed By Diffusion Tensor Imaging. *Plos One*, 5, E15219.
- Liu, M., Concha, L., Beaulieu, C. & Gross, D. W. (2011). Distinct White Matter Abnormalities In Different Idiopathic Generalized Epilepsy Syndromes. *Epilepsia*, 52, Pp.2267-75.
- Oldendorf, W. H. (1984). The Use And Promise Of Nuclear Magnetic Resonance Imaging In Epilepsy. *Epilepsia*, 25 Suppl 2, Pp.S105-17.
- Oyegbile, T., Hansen, R., Magnotta, V., O'leary, D., Bell, B., Seidenberg, M. & Hermann, B. P. (2004). Quantitative Measurement Of Cortical Surface Features In Localization-Related Temporal Lobe Epilepsy. *Neuropsychology*, 18, Pp.729-737.
- Seyedi, S., Jafari, R., Talaei, A., Naseri, S., Momenzhad, M., Moghaddam, M. D. & Akbari-Lalimi, H. (2020). Comparing Vbm And Roi Analyses For Detection Of Gray Matter Abnormalities In Patients With Bipolar Disorder Using Mri. *Middle East Current Psychiatry*, 27.
- Sidhu, M. K., Duncan, J. S. & Sander, J. W. (2018). Neuroimaging In Epilepsy. *Curr Opin Neurol*, 31, Pp.371-378.
- Sostman, H. D., Spencer, D. D., Gore, J. C., Spencer, S. S., Holcomb, W. G., Williamson, P. D., Prichard, J., Camputaro, C., Greenspan, R. H. & Mattson, R. H. (1984). Preliminary Observations On Magnetic Resonance Imaging In Refractory Epilepsy. *Magn Reson Imaging*, 2, Pp.301-6.
- Thijs, R. D., Surges, R., O'brien, T. J. & Sander, J. W. (2019). Epilepsy In Adults. *Lancet*, 393, Pp.689-701.
- Tu, Y., Wang, J., Xiong, F. & Gao, F. (2022). Cortical Abnormalities In Patients With Fibromyalgia: A Pilot Study Of Surface-Based Morphometry Analysis. *Pain Med*, 23, Pp.1939-1946.
- Tu, Y., Wang, J., Xiong, F. & Gao, F. (2022). Cortical Abnormalities In Patients with Fibromyalgia: A Pilot Study of Surface-Based Morphometry Analysis. *Pain Med*, 23, pp.1939-1946.