

A SYSTEMATIC CHARACTERIZATION OF STRUCTURAL BRAIN CHANGES IN EPILEPSY USING MAGNETIC RESONANCE IMAGING

Daswatte MRAU¹, Grero P.R.¹, David A.A.¹, Jayarathne R.E.P.¹, Pallewatte A.S.², Ediri Arachchi W.M.¹

Department of Radiography and Radiotherapy, Faculty of Allied Health Sciences, General Sir John Kotelawala Defence University, Sri Lanka¹.


Department of Radiology, National Hospital of Sri Lanka, Sri Lanka².

ABSTRACT

Grey matter and white matter changes in epilepsy detected by Voxel-based morphometry (VBM) and Tensor-based morphometry (TBM) show notable similarities and differences to date. Therefore, a direct comparison of results using VBM and TBM is necessary to understand how different methods are sensitive in detecting structural brain changes in epilepsy. 45 patients with epilepsy (27.62 ±12.8 years old) and 46 healthy controls (34.25 ±16.0 years old) were scanned using a 3 Tesla MRI scanner. T1 weighted brain images were acquired, pre-processed, and further analyzed using Computational Anatomy Toolbox (CAT12). For VBM, voxel-wise grey matter volumes, white matter volumes and cerebrospinal fluid volumes were computed and smoothed (Full width at half maximum, FWHM= 8 mm) for each participant. For TBM, voxel-wise Jacobian determinant images were obtained and smoothed (FWHM= 8 mm). The group differences between patients and healthy controls were obtained using two-sample T-tests. Conjunction analyses were performed to explore the sensitivity of different methods in detecting grey matter and white matter. Our results showed that although both methods detected widespread structural changes, there are similarities and differences in grey matter and white matter findings detected by different methods. Only 35.07 % of grey matter (cerebellum, right temporal gyrus, left cuneus and left superior frontal) were commonly detected by VBM and TBM while only 26.08 % of white matter (anterior lobe of cerebellum, left occipital, frontal, and right temporal regions) were commonly detected by VBM and TBM. Therefore, we conclude that VBM and TBM are differently sensitive in detecting structural brain changes in epilepsy.

KEYWORDS: *Epilepsy, Grey matter, White matter, Voxel based morphometry, Tensor based morphometry*

Corresponding Author: WM Ediri Arachchi email: wasmadushanka@kdu.ac.lk

 <https://orcid.org/0000-0003-3750-8070>



This is an open-access article licensed under a Creative Commons Attribution 4.0 International License (CC BY) allowing distribution and reproduction in any medium crediting the original author and source.

1. INTRODUCTION

Epilepsy is identified as a neurological disorder that leads to altered brain activity, causing seizures, sensations, and loss of consciousness. Around 50 million people from the world population suffer from epilepsy, and it has become one of the most common neurological diseases globally and 80% of epilepsy patients are reported in low and middle-developing countries. It seems that this neurological condition is leading to a significant effect on patients' health as well as their wellbeing (Goldenberg, 2010, Sidhu et al., 2018).

Based on current evidence, neuroimaging scientists believe that structural and functional alterations in the brain may cause cognitive and behavioural abnormalities in patients with epilepsy. Many efforts have been made during the last few decades to map the structural and functional brain changes in epilepsy. More importantly, magnetic resonance imaging (MRI) based computational anatomy and imaging has received significant attention in searching the neuroanatomical substrates of epilepsy (Sidhu et al., 2018, Kini et al., 2016). Two methods, Voxel based morphometry (VBM) (Yasuda et al., 2010, Bernasconi et al., 2004) and Tensor based morphometry (TBM) (Tosun et al., 2011) have been extensively used to extract voxel level morphological information of the epileptic brain.

VBM is a fully automated technique in which spatially normalize the individual brains to a standard template and segment the different tissue types and then compute voxel-wise concentrations or volumes as GM, WM, and CSF (Ashburner and Friston, 2000, Beal et al., 2013). TBM characterizes voxel-wise gross volume changes following the deformation fields which are derived by normalizing the individual brains to a standard template. Further, it is a methodological alternative to detect gross volume changes of brain without computing volume information separately for different tissue types (Ashburner et al., 1998). The above two methods have been used to detect brain changes in epilepsy and they are evidenced with certain changes in focal and whole brain changes associated with epilepsy. Notably, apart from overall grey matter volume reduction of the entire brain, GM

volume reductions in hippocampal region and thalamus has been suggested for underlying hallmark symptoms of epilepsy. In addition, there may be more extensive sclerosis in surrounding structures like amygdala and para-hippocampal gyrus (Malmgren and Thom, 2012). Reports of juvenile myoclonic epilepsy confirm thalamus and frontal cortex as mostly affected areas by its condition (Kim et al., 2007). Furthermore, literature confirms that above GM changes are not existing alone and may be associated with many WM changes including inferior longitudinal fasciculus, and superior longitudinal fasciculus, corpus callosum and uncinate fasciculus (Xu et al., 2018). Regional gross volumetric deficits in the hippocampus have also been well documented in many TBM studies (Kim et al., 2011, Kim et al., 2013).

The results found to date using VBM and TBM in epilepsy show many similarities and differences. In such ground, we believe that some areas of the epileptic brain are affected more intensively and therefore the tendency to detect such changes by both methods are highly possible whereas some other areas are affected in a specific way and may be detected by either method. Therefore, a systematic and direct comparison of the structural changes in epilepsy based on VBM and TBM is required to test the above hypothesis, which would enable an understanding how different methods are sensitive in detecting structural brain changes in epilepsy. However, such systematic studies are very rare.

2. METHODOLOGY

Subjects

46 healthy controls (8 females; 34.25 ± 16.0 years old) and 45 epilepsy patients (8 females; 27.62 ± 12.8 years old) were included in the study. The study was approved by the ethical review committees of National Hospital of Sri Lanka and Faculty of Medicine, General Sir John Kotelawala Defence University. MRI brain scans which were confirmed as generalized epilepsy were selected from the imaging database of Department of Radiology, National Hospital of Sri Lanka. The patients had been first diagnosed by neurologists using diagnostic manual published by International League Against Epilepsy (ILAE) by the evaluations including patient history,

electroencephalography (EEG) recordings and neuropathological examination. Healthy participants with the absence of any neurological or psychological illnesses were also included in the study.

Magnetic resonance image acquisition

All participants underwent brain MRI scans that were performed using a 3 Tesla scanner (Philips Ingenia 3T) and 3D, T1-weighted images were acquired: echo time (TE) = 3.1 ms; inversion time (TI) = 900 ms; flip angle (FA) = 80; repetition time (TR) = 2200 ms; matrix = 256 x 256; slice thickness = 1 mm; field of view (FOV) = 226 mm x 290 mm; no gap; 188 sagittal slices.

Image preprocessing

The orientation of three-dimensional T1W images was checked for same orientation as the priors of SPM 12 (12th version of Statistical Parametric Mapping). They were pre-processed (bias-corrected, noise removed, intensity normalized) using the CAT12 (Computational Anatomy Toolbox- a powerful suite of tools for morphometric analyses with an intuitive graphical user interface) (Christian et al., 2022) and SPM12 toolboxes. Then, the pre-processed images were subjected to undergoing VBM and TBM analyses using CAT12 toolbox.

Voxel Based Morphometry

For VBM, pre-processed images were spatially normalized (this step is essential prior to performing statistical analysis) to MNI (Montreal Neurological Institute) template and then each brain was segmented into GM, WM, and CSF tissue classes using segmentation module of CAT12. Spatially registered data were displayed as single slices of each participant to check the quality of images and to detect possible native volume artifacts. In addition, sample homogeneity was also checked. We did not detect any images as outliers and none of them were removed. The segmented images were modulated to preserve the total amount of GM, WM, or CSF in the original image. This procedure resulted in volume images of GM, WM, and CSF respectively. Each volume image of participant was spatially smoothed using an isotropic Gaussian kernel with 8-mm full-width at half-maximum (FWHM). The total intracranial

volume (TIV) of each brain was used in the model of subsequent statistical analysis to remove the inter-individual differences to produce relative volumes rather than absolute volumes.

Tensor Based Morphometry

For TBM, voxel-wise Jacobian determinants (measuring the changes in regional tissue volumes using the deformation field derived from warping the MNI template to each individual brain) were obtained and smoothed (FWHM = 8 mm). This TBM process did not involve tissue segmentation rather it was matched with the anatomical correspondence in between the reference template and each image. Voxel level volume changes and positional displacements were originally recorded in deformation fields derived by spatial matching. Then the local Jacobian determinants were derived to quantify the local volume changes for each voxel. Finally, the Jacobian determinant values greater than one were taken as volume enlargement, whereas Jacobian determinant values less than one were taken as volume reduction (Gaser et al., 1999).

Univariate Statistical Comparison

We conducted Two-sample t test to find out group differences between patients with epilepsy and healthy controls using the statistical module available in CAT12. We used VBM-GM volumes, VBM-WM volumes, VBM-CSF volumes and TBM gross volumes separately at each statistical test comparison. In this analysis, we used age and gender as covariates in the model. For VBM, TIV was used as an additional covariate (TIV was quantified using ‘Get TIV’ module of cat12). It should be noted that TIV should not be taken as an additional covariate for TBM because inter-individual differences of brains are originally removed when deriving the deformation fields. The corrected results for family-wise error (FWE) at voxel level ($p < 0.05$) were presented.

Conjunction analysis

Further, conjunction analyses were performed between GM volume changes detected by VBM and TBM and between WM volume changes detected by VBM and TBM separately. We used grey matter and white matter masks to extract grey matter and white matter

information from gross volume changes detected by TBM (Ediri Arachchi et al., 2020). Image processing steps are shown in Figure 1.

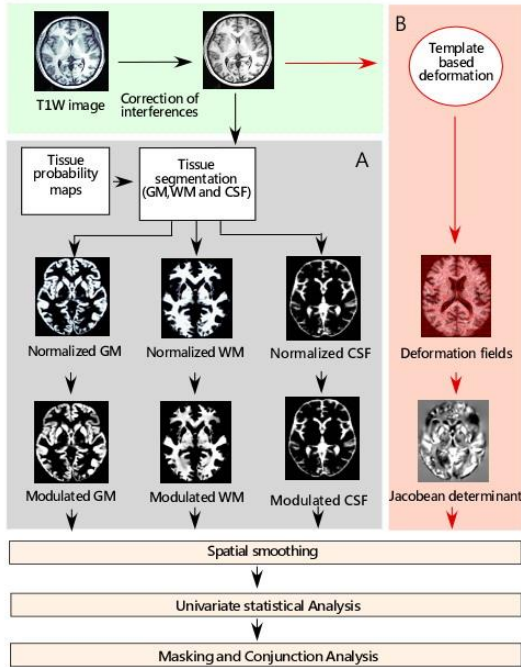


Figure 1: Image-processing workflow of Voxel-based morphometry (VBM; grey in A) and Tensor-based morphometry (TBM; red in B). GM, grey matter; WM, white matter; CSF, cerebrospinal fluid.

3. RESULTS

Univariate statistical comparisons

We found widespread volume reductions (Grey matter, white matter, and gross tissue) in epileptic brains compared to healthy controls covering both hemispheres. The results are shown in Figure 2 and summarized in tables 1 and 2. Compared with VBM, TBM was more sensitive and was able to detect more anatomical changes in the epileptic brain, more specifically the white matter, compared with VBM derived white matter.

The gross volume reductions were observed in the regions of cerebellum, cuneus, middle occipital, superior occipital, precuneus, lingual, middle temporal, superior temporal, inferior temporal and

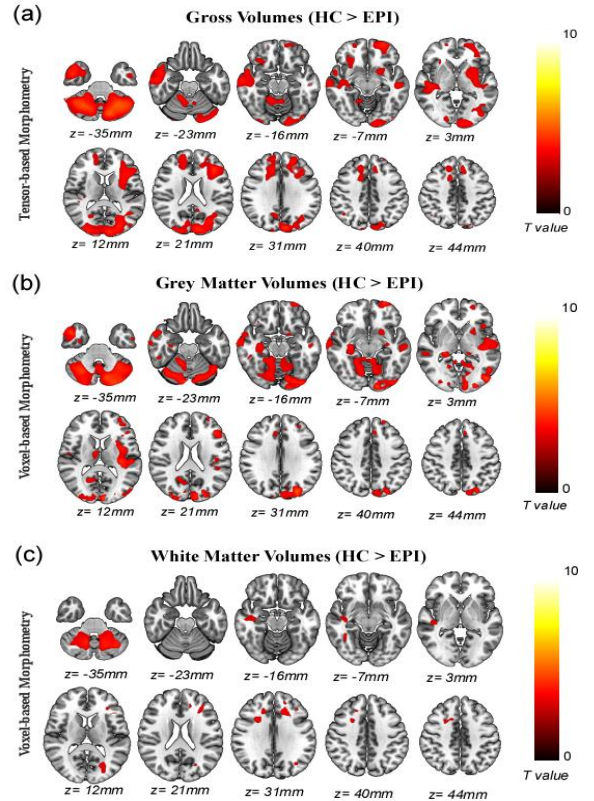


Figure 2: Regional gross volume abnormalities in patients with epilepsy compared to healthy controls detected by Tensor-based morphometry (panel a). Regional grey matter volumes (panel b) and white matter volumes (panel c) detected by Voxel-based morphometry. All detected areas, indicated in black to white (corresponding to T values obtained from two-sample t tests), had reduced volumes in patients with epilepsy compared with healthy controls. ($p < 0.05$, FWE Corrected).

inferior frontal. In addition, unilateral GM reductions were found in left superior frontal, right fusiform, right hippocampus, right superior parietal, right inferior occipital, left postcentral, left thalamus, right medial frontal, and right cingulate, left middle frontal, left putamen and left insula. The main white matter contribution was reported from cerebellum. In addition, extra nuclear, sub lobar and sub gyral white matter were highlighted from frontal and temporal lobes (Figure 2 a).

VBM has demonstrated several GM impairments in the epilepsy group in comparison to healthy controls. Bilateral grey matter volume reductions were found in cerebellum, middle occipital, middle temporal gyrus and superior occipital, cuneus and parahippocampus. In addition, unilateral GM reductions were found in right fusiform, left insula, right hippocampus, right thalamus and left superior frontal (Figure 2 b). Apart from GM findings, this study was also able to distinguish white matter volume reductions in anterior and posterior lobes of cerebellum. Compared to cerebellum, slight WM reductions were noted in sub gyral regions of frontal, left occipital, right temporal, and left occipital (Figure 2 c). It should be noted that we did not detect CSF changes in TBM or VBM.

Table 1: Regional gross volume reductions detected by tensor-based morphometry (TBM) in patients with epilepsy compared to healthy controls.

Cluster No.	Atlas region	Peak MNI Coordinates	t Value	Cluster size (Voxels)
Gross Volume changes				
1	Cerebellum, cuneus, middle occipital, superior occipital, precuneus, lingual, cerebellar white matter	-31.5, -60, -37.5	5.25	44790
2	Left superior frontal, left middle frontal, left putamen, left insula, left inferior frontal, left middle temporal, left superior temporal, sub lobar and sub gyral white matter	-37.5, 30, 22.5	4.53	15537
3	Right middle temporal, right superior temporal, right inferior temporal, right fusiform, extra nuclear, right hippocampus	46.5, 3, -33	4.45	9714
4	Right superior frontal, right medial frontal, right cingulate, sub gyral white matter	15, 28.5, 31.5	3.93	5791
5	Right inferior frontal, sub lobar white matter, extra nuclear white matter,	27, 27, -12	3.53	969
6	Right superior parietal	21, -63, 66	4.24	762
7	Left inferior temporal	-49.5, -3, -31.5	3.43	274
8	Right inferior occipital	27, -91.5, -19.5	3.50	254

Statistical significance was thresholded at $p < 0.05$, FWE Corrected. Atlas regions were defined based on the AAL atlas. Age and gender were used as covariates. MNI, Montreal Neurological Institute; L, left; R, right.

Similarities and Differences in GM changes detected by different methods

Conjunction analysis revealed a considerable overlap (35.07%) in the identified GM structural changes in patients with epilepsy across VBM and TBM methods. This overlap includes several regions such as cerebellum, right temporal gyrus, left cuneus and left superior frontal gyrus (Figure 3 a, brown areas).

Table 2: Regional grey matter (GM) and white matter (WM) volume reductions detected by voxel-based morphometry (VBM) in patients with epilepsy compared to healthy controls.

Cluster No.	Atlas region	Peak MNI Coordinates	t Value	Cluster size (Voxels)
GM Volume changes				
1	Cerebellum, left middle occipital, left superior occipital, Cuneus, left para hippocampus, Left middle temporal, right fusiform.	-9, -94.5, 7.5	5.76	28718
2	Left insula	-37.5, -21, 6	5.14	5274
3	Right middle temporal	45, 6, -36	4.69	2522
4	Right hippocampus, right para hippocampus	22.5, -33, 1.5	4.13	1215
5	Right middle occipital, right superior occipital, right cuneus	16.5, -96, 10.5	4.16	998
6	Left superior frontal	-27, 63, -12	4.25	471
7	Right thalamus	6, -7.5, 12	3.62	398
8	Right fusiform	28.5, -1.5, 43.5	3.92	295
9	Right middle temporal	54, -34.5, -4.5	4.02	225
WM Volume changes				
1	Left cerebellum posterior lobe, left cerebellum anterior lobe.	-37.5, -57, -37.5	4.58	2822
2	Right cerebellum posterior lobe, right cerebellum anterior lobe.	40.5, -51, -39	4.46	2426
3	Sub gyral (Left frontal)	-19.5, 48, 27	3.98	940

Statistical significance was thresholded at $p < 0.05$, FWE Corrected. Atlas regions were defined based on the AAL atlas. Age and gender were used as covariates. MNI, Montreal Neurological Institute; L, left; R, right.

Apart from overlaps some regional GM structural changes (27.03%) in volume space were only detected by VBM, but not by TBM (Figure 3 a, red areas). These areas include the left insula and right

cerebellum. Further, several GM volume reductions were only detected by TBM (37.88%), but not by VBM (Figure 3 a, green areas). These regions include the left putamen, middle occipital gyrus and superior frontal gyrus.

Similarities and Differences in WM changes detected by different methods.

We noticed considerable overlaps of WM results (26.08%) detected by VBM and TBM. Commonly detected white matter areas were mostly associated with anterior lobe of cerebellum, left occipital, frontal, and right temporal regions (Figure 3b, brown areas). Further, it should be noted that TBM alone has been able to detect several scattered white matter volume reductions (71.4%) covering frontal, occipital and temporal lobes of the cerebrum (Figure 3b, green areas). However, we did not find a significant amount of WM reduction detected by VBM alone (2.5%).

4. DISCUSSION

We used two popular methods (VBM and TBM) to characterize structural brain changes in epilepsy. The aim of the study was to investigate how different methods are sensitive in detecting structural brain changes in epilepsy. The main strengths of this study are two folds. First, comparing results from different studies does not allow direct comparisons between results obtained using different methods due to the use of different sample sizes, different stages of illness, changes in medication level of subjects and distinct data processing strategies applied in different studies. Second, although structural changes detected by these different methods are likely to be related to each other, they also capture information from different aspects and thus are likely to have different sensitivity in detecting different types of structural changes.

We observed two main findings with respect to each tissue type. First, regarding the structural changes, each tissue type is associated with wide-spread volume reductions in epilepsy, but a portion of these structural changes were commonly detected by both methods. Second, in addition to overlaps we detected, several regional volume reductions which are only specific to the structural method applied were also reported. For an example, significant amount of non-overlapping or method specific regions in grey matter were found by both TBM and VBM respectively. Further, TBM was able to detect large amounts of white matter regions which are independent from overlapping. Therefore, it is obvious that although structural changes detected by these different methods are likely to be related to each other, they also capture information from different aspects and thus are likely to have different sensitivity in detecting different types of structural changes.

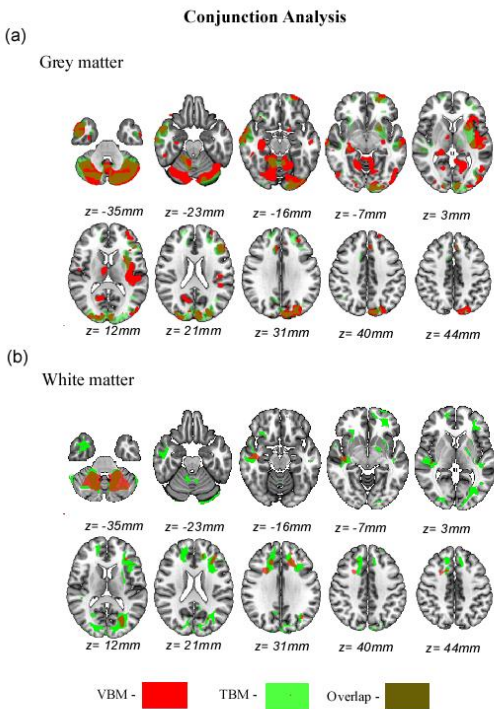


Figure 3: Conjunction analysis of grey matter detected by Voxel-based morphometry and Tensor-based morphometry (panel a) and white matter detected by Voxel-based morphometry and Tensor-based morphometry (panel b)

superior frontal) (Jobst et al., 2019, Lu et al., 2022). Amongst grey matter regions cerebellum was specifically noted by both methods. Although the cerebellum is not traditionally associated with epilepsy there is plenty of evidence to show that cerebellum plays a significant role in seizure networks (Streng and Krook-Magnuson, 2021, Ibdali et al., 2021). Reduced white matter volumes associated with cerebellum was mostly highlighted and scattered reductions were shown in frontal, occipital and temporal regions (Tae et al., 2010, Slinger et al., 2016). Deformation based studies conducted to date on epilepsy have revealed more pronounced tissue volume reductions in frontal parietal and temporal regions (Tosun et al., 2011). Among sub-cortical regions hippocampus have been the most featuring anatomical region in literature whereas we did not detect bilateral volume reductions in hippocampus with TBM, rather it was only confined to the right side (Kim et al., 2013).

GM findings detected by VBM have been considerably confirmed by gross volume changes detected by TBM. But VBM has failed to confirm or TBM has detected more white matter volume changes in epilepsy. In addition to GM and WM, we were interested in presenting possible CSF changes associated with epilepsy. However, we did not observe any significant changes in CSF. It is not surprising that the literature has hardly reported the involvement of CSF changes in epilepsy.

VBM approach applied in this study converts the original density value of the GM (or the WM) into the absolute volume of the given tissue type, and then removes the effects of global brain volume by regressing out the TIV during the statistical comparisons and obtained relative volumes at voxel level. The TBM approach applied in this study can restrict information on deformation fields to local volume changes, by using the local Jacobian determinant of the deformation matrix at each voxel. This can be seen as a shrinkage or enlargement of the volume. It is important to note that TBM does not distinguish different tissue types (GM, WM, and CSF) within a particular voxel, but it quantifies the gross volume changes at voxel level. As VBM and TBM are closely related, one may expect close relationships between the findings of grey matter and white matter.

For an example, one would expect that the gross volume reductions detected by TBM may indicate reduced GM volume, WM volumes and CSF volumes (measured by VBM). Because theoretically the gross volume of tissues comprises all three tissue types such as GM volumes, WM volumes and CSF volumes.

We believe that the similarities and differences found in the findings of the present study could be explained by methodological properties or their sensitivities to detect different structural information of brain. In principle, TBM follows the method of mapping each point of the template to corresponding point of the image based on displacement vector and Jacobean matrix. Therefore, the tendency of the occurrence of registration errors at TBM is more prone than at VBM. Therefore, we believe TBM contains more noise in comparison to VBM. Further, the possibility of the occurrence of errors would be much increased when the registration uncertainty is higher. Apart from that VBM is suggested as the more powerful method of detecting local anatomical changes in comparison to TBM (Davatzikos et al., 2001, Eckert et al., 2006, Ediri Arachchi et al., 2020b, Khan et al., 2015, Yushkevich et al., 2005, Borghammer et al., 2010). In summary, inherent methodological alterations of VBM and TBM could be directly related with the finding derived from them.

5. CONCLUSION

We conclude that although both methods detected widespread structural changes, there are similarities and differences in GM and WM findings. Therefore, we confirm that VBM and TBM are differently sensitive in detecting structural brain changes in epilepsy.

6. REFERENCES

- Alvim, M. K., Coan, A. C., Campos, B. M., Yasuda, C. L., Oliveira, M. C., Morita, M. E. and Cendes, F. (2016). 'Progression of gray matter atrophy in seizure-free patients with temporal lobe epilepsy', *Epilepsia*, 57(4): pp. 621-9. 10.1111/epi.13334.
- Ashburner, J. and Friston, K. J. (2000). 'Voxel-based morphometry--the methods', *Neuroimage*, 11(6 Pt 1): pp. 805-21. 10.1006/nimg.2000.0582.

- Ashburner, J., Hutton, C., Frackowiak, R., Johnsrude, I., Price, C. and Friston, K. (1998). 'Identifying global anatomical differences: deformation-based morphometry', *Hum Brain Mapp*, 6(5-6): pp. 348-57.
- Beal, D. S., Gracco, V. L., Brettschneider, J., Kroll, R. M. and De Nil, L. F. (2013). 'A voxel-based morphometry (VBM) analysis of regional grey and white matter volume abnormalities within the speech production network of children who stutter', *Cortex*, 49(8): pp. 2151-61. 10.1016/j.cortex.2012.08.013.
- Bernasconi, N., Duchesne, S., Janke, A., Lerch, J., Collins, D. L. and Bernasconi, A. (2004). 'Whole-brain voxel-based statistical analysis of gray matter and white matter in temporal lobe epilepsy', *Neuroimage*, 23(2): pp. 717-23. 10.1016/j.neuroimage.2004.06.015.
- Borghammer, P., Ostergaard, K., Cumming, P., Gjedde, A., Rodell, A., Hall, N. and Chakravarty, M. M. (2010). 'A deformation-based morphometry study of patients with early-stage Parkinson's disease', *Eur J. Neurol*, 17(2): pp. 314-20. 10.1111/j.1468-1331.2009.02807.
- Christian, G. R., Dahnke. (2022). CAT – A Computational Anatomy Toolbox for the Analysis of Structural MRI Data. 10.1101/2022.06.11.495736
- Davatzikos, C., Genc, A., Xu, D., & Resnick, S. M. (2001). Voxel-based morphometry using the RAVENS maps: methods and validation using simulated longitudinal atrophy. *Neuroimage*, 14(6), pp.1361-1369. 10.1006/nimg.2001.0937
- Eckert, M. A., Tenforde, A., Galaburda, A. M., Bellugi, U., Korenberg, J. R., Mills, D., & Reiss, A. L. (2006). To modulate or not to modulate: differing results in uniquely shaped Williams syndrome brains. *Neuroimage*, 32(3): pp.1001-1007. 10.1016/j.neuroimage.2006.05.014
- Ediri Arachchi, W., Peng, Y., Zhang, X., Qin, W. and Zhuo, C. (2020). 'A Systematic Characterization of Structural Brain Changes in Schizophrenia', 36(10): pp. 1107-1122. 10.1007/s12264-020-00520-8.
- Gaser, C., Volz, H. P., Kiebel, S., Riehemann, S. and Sauer, H. (1999). 'Detecting structural changes in whole brain based on nonlinear deformations-application to schizophrenia research', *Neuroimage*, 10(2): pp. 107-13. 10.1006/nimg.1999.0458.
- Goldenberg, M. M. (2010). 'Overview of drugs used for epilepsy and seizures: etiology, diagnosis, and treatment', *P T*, 35(7): pp. 392-415.
- Ibdali, M., Hadjivassiliou, M., Grunewald, R. A. and Shanmugarajah, P. D. (2021). 'Cerebellar Degeneration in Epilepsy: A Systematic Review', *Int. J. Environ Res Public Health*, 18(2). 10.3390/ijerph18020473.
- Jobst, B. C., Gonzalez-Martinez, J., Isnard, J., Kahane, P., Lacey, N., Lahtoo, S.D., Nguyen, D. K., Wu, C. and Lado, F. (2019). 'The Insula and Its Epilepsies', *Epilepsy Curr*, 19(1), pp. 11-21. 10.1177/1535759718822847.
- Khan, A. R., Wang, L. and Beg, M. F. (2015). 'Unified voxel- and tensor-based morphometry (UVTBM) using registration confidence', *Neurobiol Aging*, 36 Suppl 1(Suppl 1), pp. S60-8. 10.1016/j.neurobiolaging.2014.04.036.
- Kim, H., Mansi, T., Bernasconi, A. and Bernasconi, N. (2011). 'Vertex-wise shape analysis of the hippocampus: disentangling positional differences from volume changes', *Med. Image Comput. Assist Interv*, 14(Pt 2): pp. 352-9. DOI: 10.1007/978-3-642-23629-7_43.
- Kim, H., Mansi, T. and Bernasconi, N. (2013). 'Disentangling hippocampal shape anomalies in epilepsy', *Front Neurol.*, 4, pp. 131. 10.3389/fneur.2013.00131.
- Kim, J. H., Lee, J. K., Koh, S. B., Lee, S. A., Lee, J. M., Kim, S. I. and Kang, J. K. (2007). 'Regional grey matter abnormalities in juvenile myoclonic epilepsy: a voxel-based morphometry study', *Neuroimage*, 37(4): pp. 1132-7. 10.1016/j.neuroimage.2007.06.025.

- Kini, L. G., Gee, J. C. and Litt, B. (2016). 'Computational analysis in epilepsy neuroimaging: A survey of features and methods', *Neuroimage Clin.*, 11: pp. 515-529. 10.1016/j.nicl.2016.02.013.
- Latini, F., Hjortberg, M., Aldskogius, H. and Ryttefors, M. (2015) 'The Classical Pathways of Occipital Lobe Epileptic Propagation Revised in the Light of White Matter Dissection', *Behav. Neurol.*, 2015, pp. 872645. 10.1155/2015/872645.
- Lu, C. Q., Gosden, G. P., Okromelidze, L., Jain, A., Gupta, V., Grewal, S. S., Lin, C., Tatum, W. O., Messina, S. A., Quiñones-Hinojosa, A., Ju, S. and Middlebrooks, E. H. (2022). 'Brain structural differences in temporal lobe and frontal lobe epilepsy patients: A voxel-based morphometry and vertex-based surface analysis', *Neuroradiol. J.*, 35(2): pp. 193-202. 10.1177/19714009211034839.
- Malmgren, K. and Thom, M. (2012). 'Hippocampal sclerosis--origins and imaging', *Epilepsia*, 53 Suppl 4: pp. 19-33. 10.1111/j.1528-1167.2012.03610.x.
- Peng, Y., Zhang, X., Li, Y., Su, Q., Wang, S., Liu, F., Yu, C. and Liang, M. (2020) 'MVPANI: A Toolkit With Friendly Graphical User Interface for Multivariate Pattern Analysis of Neuroimaging Data', *Front Neurosci.*, 14, pp. 545. 10.3389/fnins.2020.00545.
- Sidhu, M. K., Duncan, J. S. and Sander, J. W. (2018). 'Neuroimaging in epilepsy', *Curr. Opin. Neurol.*, 31(4): pp. 371-378. 10.1097/WCO.0000000000000568.
- Slinger, G., Sinke, M. R., Braun, K. P. and Otte, W. M. (2016). 'White matter abnormalities at a regional and voxel level in focal and generalized epilepsy: A systematic review and meta-analysis', *Neuroimage Clin.*, 12, pp. 902-909. 10.1016/j.nicl.2016.10.025.
- Streng, M. L. and Krook-Magnuson, E. (2021). 'The cerebellum and epilepsy', *Epilepsy Behav.*, 121(Pt B): pp. 106909. 10.1016/j.yebeh.2020.106909.
- Tae, W. S., Joo, E. Y., Kim, S. T. and Hong, S. B. (2010). 'Gray, white matter concentration changes and their correlation with heterotopic neurons in temporal lobe epilepsy', *Korean J. Radiol.*, 11(1): pp. 25-36. 10.3348/kjr.2010.11.1.25.
- Tosun, D., Dabbs, K., Caplan, R., Siddarth, P., Toga, A., Seidenberg, M. and Hermann, B. (2011). 'Deformation-based morphometry of prospective neurodevelopmental changes in new onset paediatric epilepsy', *Brain*, 134(Pt 4): pp. 1003-14. 10.1093/brain/awr027.
- Xu, S. W., Xi, J. H., Lin, C., Wang, X. Y., Fu, L. Y., Kralik, S. F. and Chen, Z. Q. (2018). 'Cognitive decline and white matter changes in mesial temporal lobe epilepsy', *Medicine (Baltimore)*, 97(33): pp. e11803. 10.1097/md.00000000000011803.
- Yasuda, C. L., Betting, L. E. and Cendes, F. (2010). 'Voxel-based morphometry and epilepsy', *Expert Rev. Neurother.*, 10(6): pp. 975-84. 10.1586/ern.10.63.
- Yushkevich, P., Dubb, A., Xie, Z., Gur, R., Gur, R. and Gee, J. (2005). 'Regional structural characterization of the brain of schizophrenia patients', *Acad. Radiol.*, 12(10): pp. 1250-61. 10.1016/j.acra.2005.06.014.